

Photopatch tests: series of 37 Brazilian patients

Maria Scherrer, Vanessa Barreto Rocha - Dermatology - Hospital das Clínicas- UFMG

Introduction

Photopatch tests (PPT) are indicated for the diagnosis of photoallergic contact dermatitis (PACD)¹. This is a delayed hypersensitivity reaction that occurs when a photoallergen is applied to the skin subsequently exposed to visible and / or ultraviolet (UV) radiation^{2,3}. Its incidence is unknown, estimated at 2-10% of patients referred for photodermatosis investigation⁴.

Patients and Methods - Results

Patients treated at the Contact Dermatitis Outpatient Clinic at Hospital das Clínicas – UFMG - Belo Horizonte between 2007 and 2019, who had been suspected to have photodermatosis after patch testing to the Brazilian standard series (BSS) were selected for the PPT for diagnostic purposes. FDA-Allergenic – RJ - Brazil and Chemotechnique Diagnostics - Sweden allergens (table 1) were used in Finn Chambers® on Scanpor® (Smartpractice-USA) or Allergochambers® (Neoflex - São Paulo - Brazil) applied in duplicate to the back skin. Removed 48 hours later, readings were taken and an allergen set was covered with a surgical pad and aluminum foil. As no patient presented a minimum erythematous dose lower than 10 J/ cm² of UVA, the other allergen set was irradiated with this dose in all patients, which was followed by immediate reading and subsequent occlusion. New readings in both sets were performed 48 hours later, following ICDRG criteria. (International Contact Dermatitis Research Group). If only the irradiated side showed a positive reaction, the diagnosis was photoallergic reaction. If both sides had a positive reaction but the irradiation was greater, it was allergic contact dermatitis (ACD) and photoallergic contact dermatitis (PACD), and if the reactions were equal on both sides, allergic contact dermatitis (ACD). (5)

Haptens	Vehicle	Photo allergic reactions
PABA 10%	vaseline	0
Oxybenzone (benzophenone-3) 10%	vaseline	3
Butylmethoxybenzoylmethane 10%	vaseline	1
Sesquiterpene lactone mix 0,1%	vaseline	1
Musk xyene 1%	vaseline	0
Balsam Peru 35%	vaseline	6
Promethazine 1%	vaseline	4
Perfume mix 7%	vaseline	5
Irgasan 1%	vaseline	0
Potassium dichromate 0,5%	vaseline	4
Chlorpromazine hydrochloride 0,1%	vaseline	9
Thiourea 0,1%	vaseline	1
Chlorhexedine 0,5%	water	4
Paraphenylenediamine 1%	vaseline	2
Compositae mix 5%	vaseline	2
BHT (butyl hydroxy toluene) 2%	vaseline	3

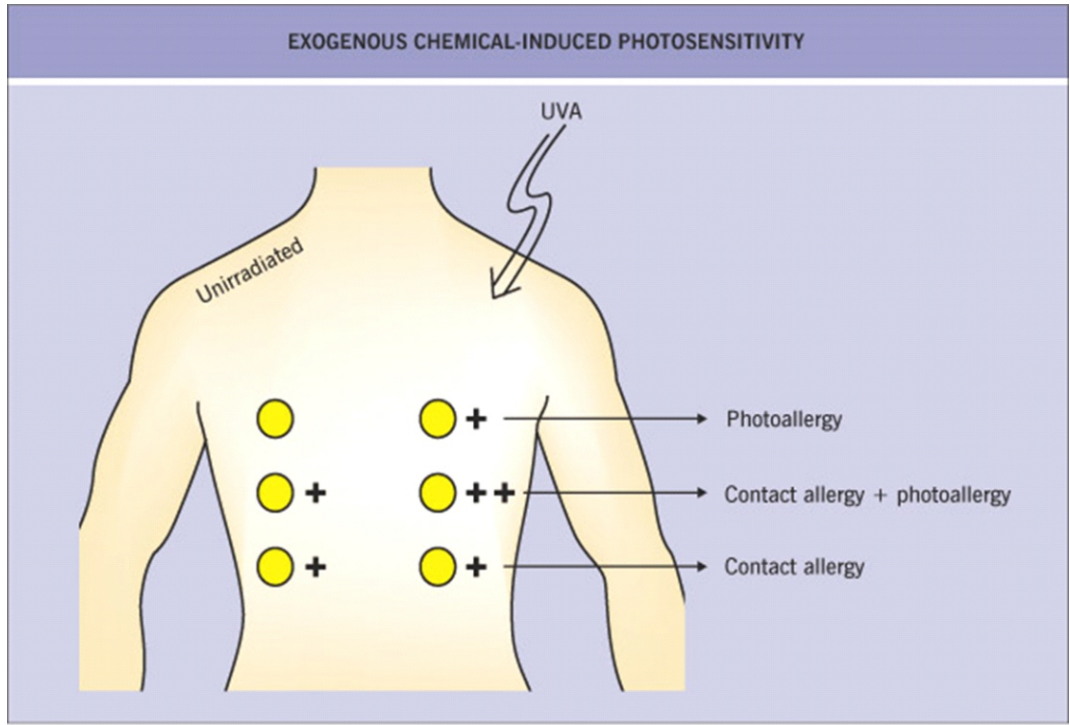
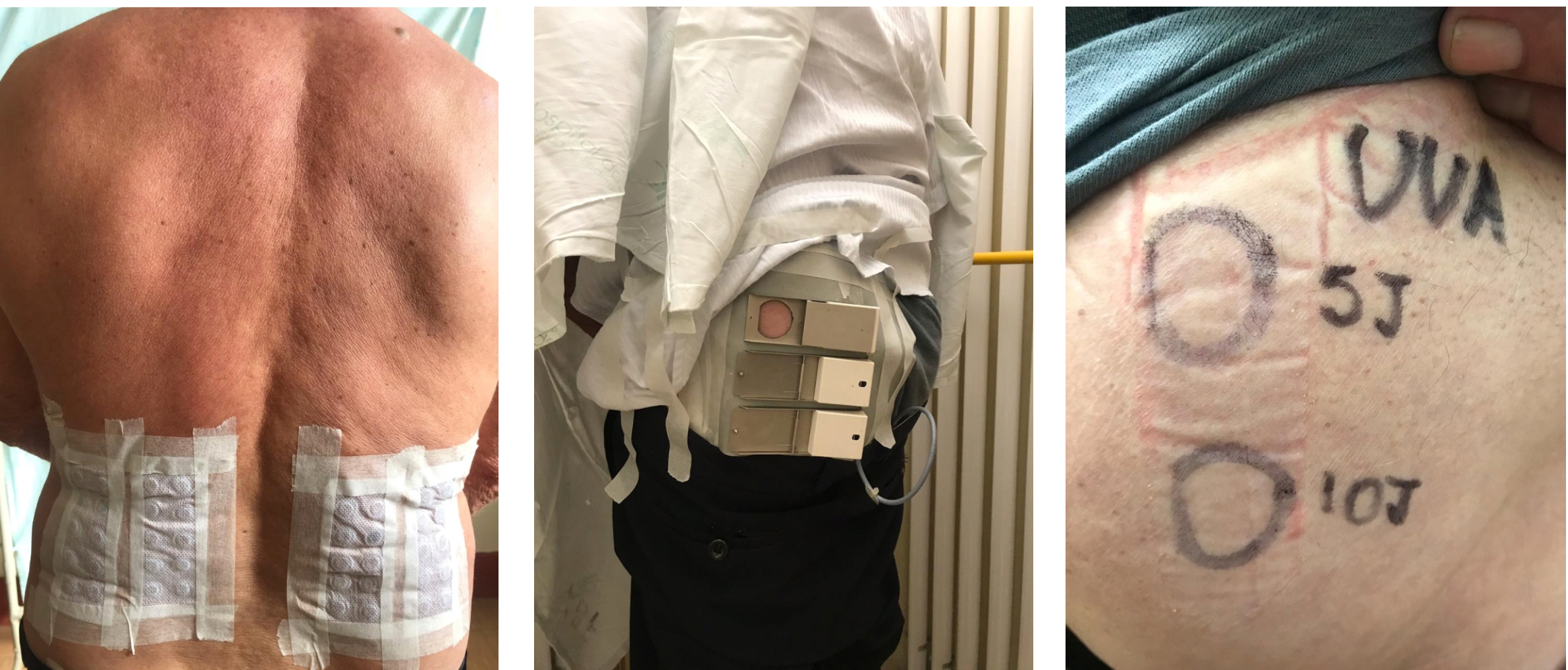

Table 1: Our photopatch test series and number of photoallergic reactions

References

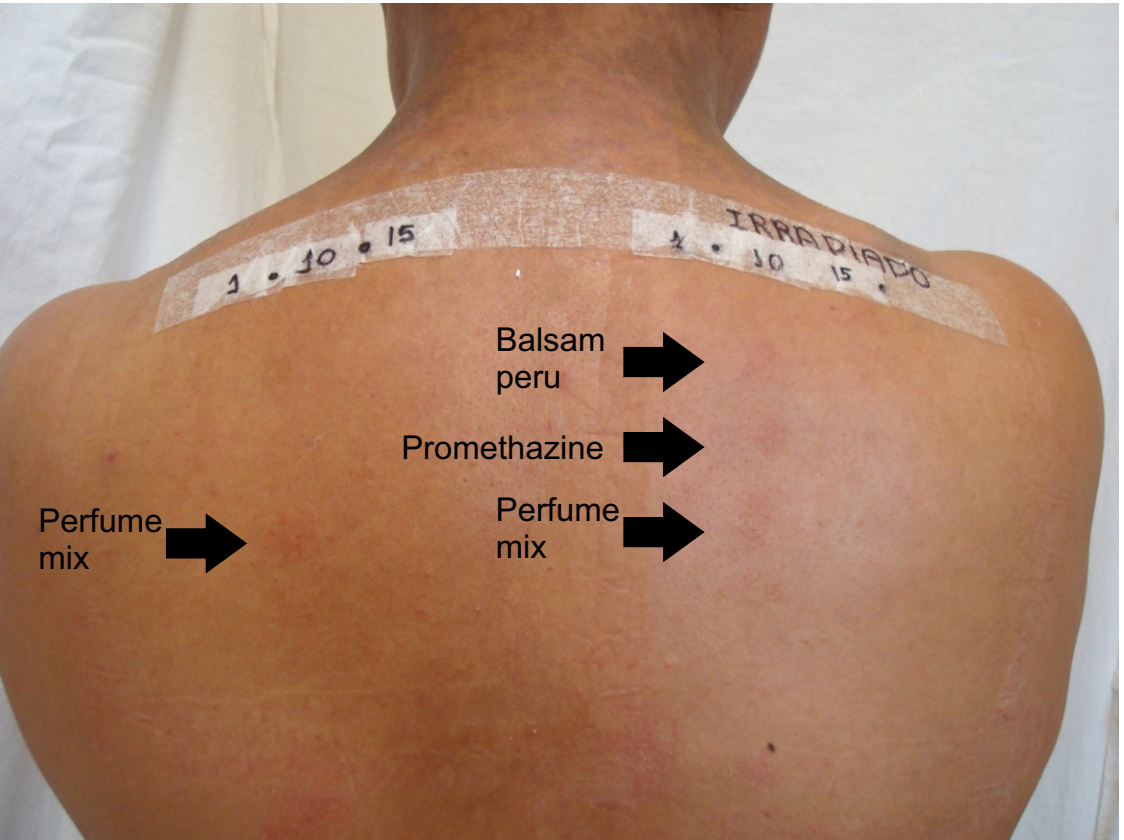
- Hu Y, Wang D, Shen Y, Tang H. Photopatch Testing in Chinese Patients Over 10 Years. *Dermatitis*. 2016;27(3):137-42.
- Subiabre-Ferrer D, Esteve-Martínez A, Blasco-Encinas R, Sierra-Talamantes C, Pérez-Ferriols A, Zaragoza-Ninet V. European photopatch test baseline series: A 3-year experience. *Contact Dermatitis*. 2019;80(1):5-8.
- Rai R, Thomas M. Photopatch and UV-irradiated patch testing in photosensitive dermatitis. *Indian Dermatol Online J*. 2016;7(1):12-6.
- Taskforce EMPTSE. A European multicentre photopatch test study. *Br J Dermatol*. 2012;166(5):1002-9.
- Fowler J, Zirwas M. Fisher's Contact Dermatitis. 7th ed. Phoenix, AZ, USA: Contact Dermatitis Institute; 2019.

First day: applying two sets of haptens, performing photo test to UVA

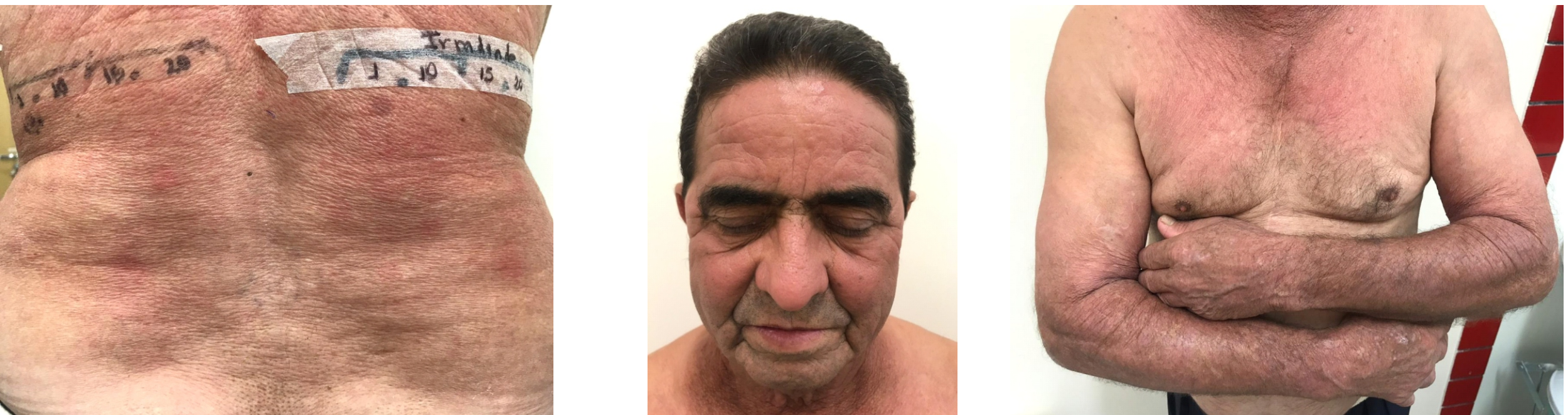

UVA photo test readings: immediate, 24 and 48 h

96 - hour Reading: ACD to Perfume mix and PACD to Balsam Peru and Promethazine

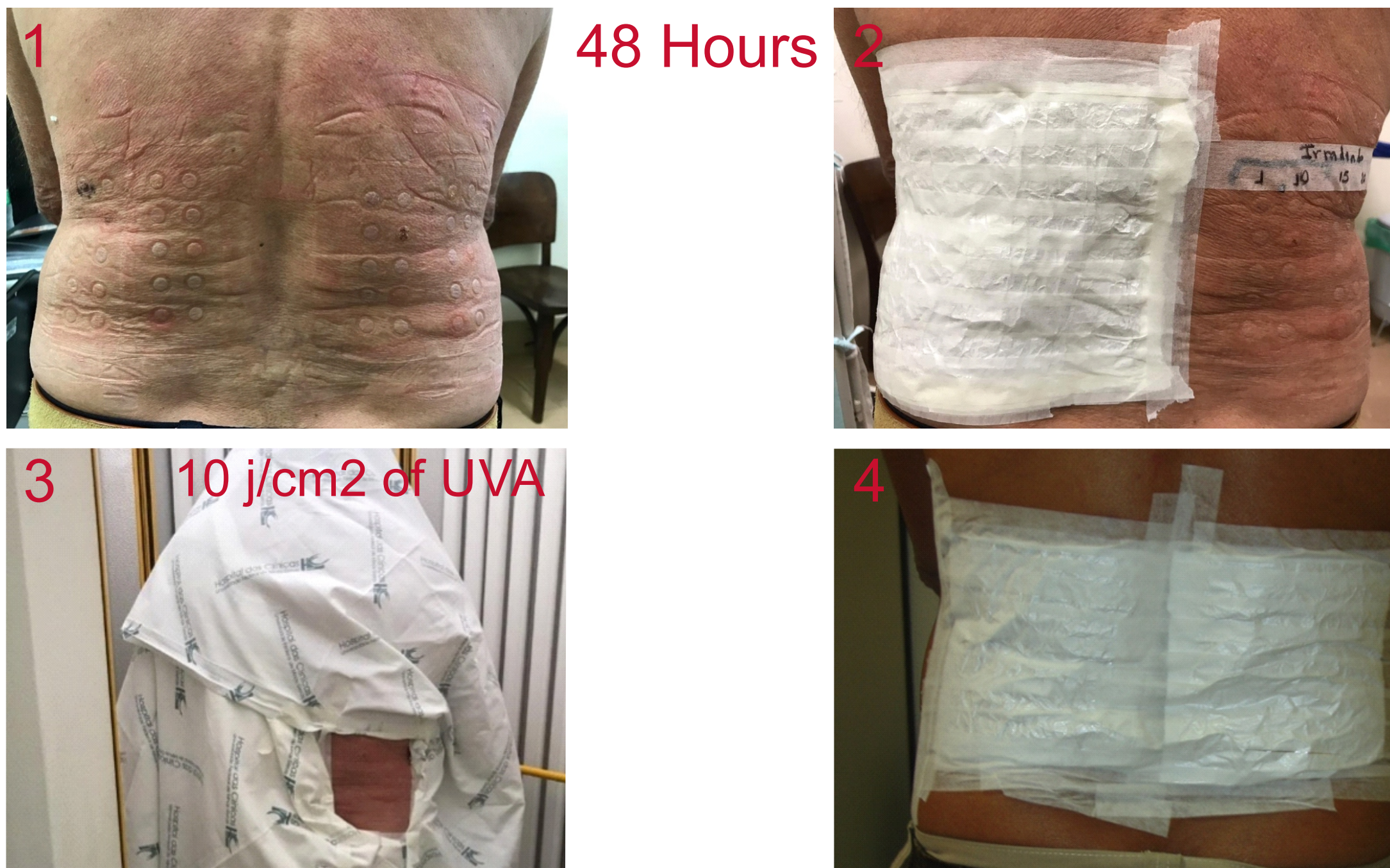

96 - hour Reading: PACD to compositae mix

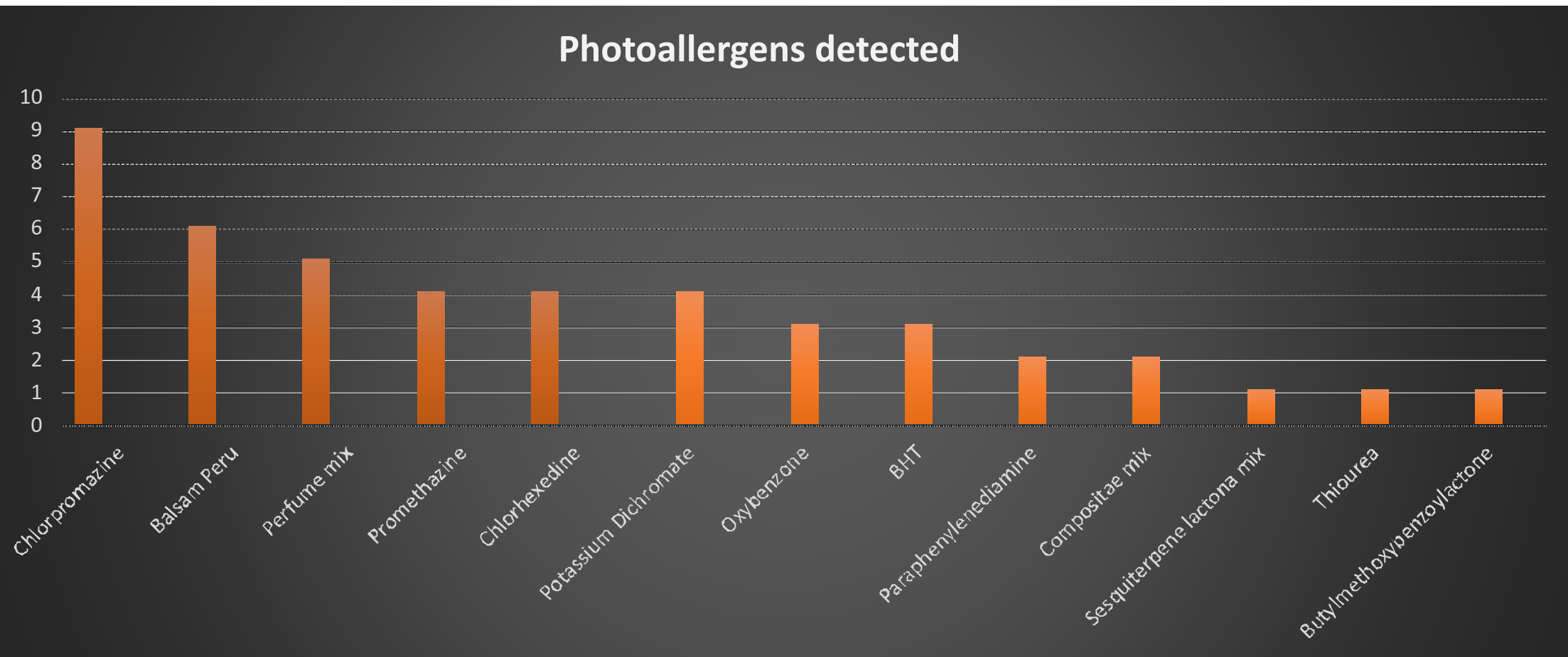
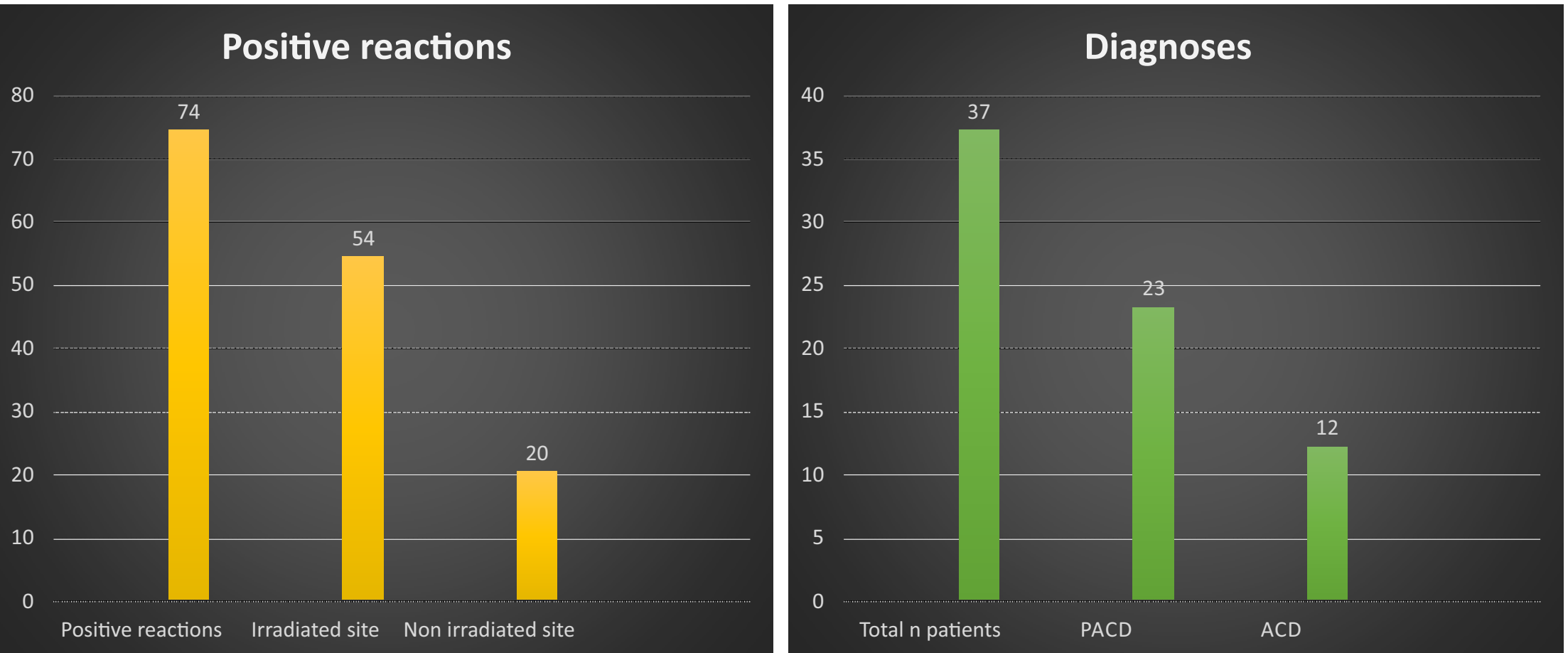


Among 1,712 patch tested patients, we selected 37 (2.2%), 19 men (51.4%) and 18 women (48.6%), aged 30-80 years, 22 (59.4%) of phototypes II and III, 7 (19%) IV and V and 8 (21.6%) VI. Six patients (16.2%) had a personal history of atopy, 15 (40.5%) related photo protection with sunscreens, 31 (84%) had varied professions, 4 (11%) were bricklayers and 2 (5.4%) farmers. The duration of the lesions ranged from 5 months to 20 years and the most affected sites were exposed areas.

Three patients (8%) presented disseminated lesions. The previous contact test showed reactions to Kathon and Quaternium 15 in one patient, Formaldehyde in one, Nickel, Thimerosal and Hydroquinone in one and Potassium Dichromate in two. Seventy four positive reactions were observed, 54 on irradiated side and 20 on non-irradiated side. Photoallergic contact dermatitis (PACD) was diagnosed in 23 (62%) patients and allergic contact dermatitis (ACD) in 12 (32%). The photoallergic reactions detected were to Chlorpromazine (n = 9, 24%), Balsam Peru (n = 6, 16%), Perfume mix (n=5, 13.5%), Promethazine, Chlorhexedine and Potassium Dichromate (n = 4, 11%), Oxybenzone and BHT (n = 3, 8%), Paraphenylenediamine and Compositae mix (n = 2, 5.4%), Sesquiterpene Lactone mix, Thiourea and Butylmethoxybenzoylactone (n = 1, 2.7%).



Results



Comments

Reactions to chlorpromazine were the most frequent in the patients investigated, as it was observed in a Chinese series¹. It is a phenothiazine-derived antipsychotic whose analogues such as dihydrochlorothiazide and promethazine are widely used as a diuretic and antipruritic drug in Brazil¹. Promethazine was the fourth photoallergen as well as chlorhexedine and potassium dichromate, but only one patient showed co-reaction between chlorpromazine and promethazine. The second in frequency was Balsam of Peru, followed by Perfume Mix.

Differences in the pattern of photopositivity vary according to the geographical area and the population studied. This is a preliminary investigation that reflects some habits of the Brazilian population, such as the oral and topical use of promethazine as antipruritic drug and the professional or domestic exposure to cement.

A Brazilian standardized PPT series like the one described above is suggested, as it is an effective and important tool in the diagnosis of photosensitive dermatitis.